

ORIGINAL PAPERS

A Pilot Study of Functional Magnetic Resonance Imaging of the Brain During Manual and Electroacupuncture Stimulation of Acupuncture Point (LI-4 Hegu) in Normal Subjects Reveals Differential Brain Activation Between Methods

JIAN KONG, M.S., Lic.Ac.,^{1,2} LIN MA, M.D., Ph.D.,³ RANDY L. GOLLUB, M.D., Ph.D.,²
JINGHAN WEI, Ph.D.,⁴ XUIZHEN YANG, M.D.,¹ DEJUN LI, Ph.D.,³
XUCHU WENG, Ph.D.,⁴ FUCANG JIA, Ph.D.,⁴ CHUNMAO WANG, Ph.D.,⁴
FULI LI, Ph.D.,⁵ RUIWU LI, M.D.,¹ and DING ZHUANG, M.D.¹

ABSTRACT

Objectives: To characterize the brain activation patterns evoked by manual and electroacupuncture on normal human subjects.

Design: We used functional magnetic resonance imaging (fMRI) to investigate the brain regions involved in electroacupuncture and manual acupuncture needle stimulation. A block design was adopted for the study. Each functional run consists of 5 minutes, starting with 1-minute baseline and two 1-minute stimulation, the interval between the two stimuli was 1 minute. Four functional runs were performed on each subject, two runs for electroacupuncture and two runs for manual acupuncture. The order of the two modalities was randomized among subjects. During the experiment, acupuncture needle manipulation was performed at Large Intestine 4 (LI4, Hegu) on the left hand. For each subject, before scanning started, the needle was inserted perpendicular to the skin surface to a depth of approximately 1.0 cm. Electroacupuncture stimulation was delivered using a continuous rectangular wave form (pulse width 30 ms) at a frequency of 3 Hz. For manual acupuncture, the needle was rotated manually clockwise and counterclockwise at a rate of about 180 times per minute (3 Hz).

Subjects: Eleven right-handed, normal, healthy volunteer adults, 6 male and 5 female, ages 21-64 participated in the experiment.

Results: Results showed that electroacupuncture mainly produced fMRI signal increases in precentral gyrus, postcentral gyrus/inferior parietal lobule, and putamen/insula; in contrast, manual needle manipulation produced prominent decreases of fMRI signals in posterior cingulate, superior temporal gyrus, putamen/insula.

Conclusion: These results indicate that different brain networks are involved during manual and electroacupuncture stimulation. It suggests that different brain mechanisms may be recruited during manual and electroacupuncture.

¹Institute of Acupuncture and Moxibustion, China Academy of Traditional Chinese Medicine, Beijing, People's Republic of China.

²Department of Psychiatry, Massachusetts General Hospital East, Charlestown, MA, and Harvard Medical School, Boston, MA.

³Department of Radiology, PLA General Hospital, Beijing, People's Republic of China.

⁴Institute of Psychology, Chinese Academy of Science, Beijing, People's Republic of China.

⁵Department of Physics, Capital Moral University, Beijing, People's Republic of China.

INTRODUCTION

Acupuncture, an ancient therapeutic technique, is emerging as an important modality of complementary medicine in Western countries (Diehl et al., 1997; Eisenberg et al., 1993, 1998). Acupuncture treatments for postoperative and chemotherapy-induced nausea and vomiting and for postoperative dental pain are promising, and acupuncture can be a beneficial adjunct or alternative treatment for drug addiction, stroke rehabilitation, asthma and chronic pain (NIH, 1998). In ancient times, acupuncturists used manual manipulation methods to achieve clinical benefits. Today, electroacupuncture is becoming more and more popular. Both acupuncture modalities are believed to have clinical efficacy, however, many research studies suggest that they work through different neural mechanisms. For instance, the two modalities have significantly different effects on electroencephalogram (EEG), salivary flow rate, and neurotransmitter release in the central nervous system (Bucinskaite et al., 1994; Dawidson et al., 1997; Saletu et al., 1975).

Recently, functional magnetic resonance imaging (fMRI) has been used to investigate the neurobiologic mechanism underlying acupuncture needle manipulation (Cho et al., 1998; Hui et al., 2000; Wu et al., 1999). In these studies, researchers investigated correlations between brain activities as reflected by fMRI signal changes and acupuncture stimuli. For example, in one study, it has been reported that manual acupuncture needle manipulation for 2 minutes at Large Intestine 4 (LI4) produced few fMRI signal increases, but widespread signal decreases in the nucleus accumbens, amygdala, hippocampus, parahippocampus, hypothalamus, ventral tegmental area, anterior cingulate gyrus (BA24), caudate, putamen, temporal pole, and insula in all subjects who experienced acupuncture sensation (Hui et al., 2000). The authors interpret this result as evidence that acupuncture needle manipulation can modulate the activity of the limbic system and subcortical structures. Two other reports also found that manual acupuncture needle manipulation can produce corresponding temporal fMRI signal changes (Cho et al., 1998; Wu

et al., 1999). These studies indicate that fMRI, a noninvasive imaging method that can detect the rapid changes in neural activity in discrete brain regions that accompany acupuncture stimulation in human subjects, can provide valuable information about the scientific basis of acupuncture.

No fMRI studies comparing the patterns of brain activation induced by the two commonly used clinical acupuncture treatment modalities, manual and electroacupuncture, have been reported. Investigation of the pattern of regional brain activation produced by manual acupuncture and electroacupuncture stimulation will not only provide more information about the biologic basis of acupuncture, but may also be helpful in explaining the different effects of the acupuncture modalities on the central nervous system. Ultimately, the information gained by imaging studies may help refine acupuncture treatment protocols to achieve maximal clinical efficacy. In this experiment, we utilized fMRI using both manual acupuncture and electroacupuncture at LI4 in the same subjects, to investigate the brain networks that are involved in these two modalities of acupuncture. The acupoint LI4 was selected because it is the most frequently used acupoint in Chinese acupuncture, especially for analgesia and sedation, and because there are previous fMRI studies using this point, facilitating comparison of results with those of other research groups (Hui et al., 2000; Wu et al., 1999).

MATERIALS AND METHODS

Subjects

The Academic and Ethical Committee in the Institute of Acupuncture, China Academy of Traditional Chinese Medicine, approved the imaging study, which was performed after obtaining informed consent. Eleven (11) right-handed normal, healthy volunteer adults, 6 male and 5 female, ages 21–64 (32 ± 16.1) participated. None had a history of psychiatric or neurologic disorders or head trauma with loss of consciousness, nor intake of tranquilizing drugs in the previous 3 days. All subjects had

received acupuncture before and had some knowledge of acupuncture (they were either students in acupuncture school or acupuncture research scientists). Thus, it was easy for them to detect different acupuncture sensations.

Experimental protocol

Each subject was put into the scanner and instructed to close his or her eyes and relax throughout the imaging session. Four MRI scan runs were performed, two runs for electroacupuncture and two for manual acupuncture. The order of the two modalities was randomized among subjects.

Acupuncture was performed at acupoint LI4 on the left hand only. Intermittent acupuncture stimulation was delivered using a sterile disposable #32 stainless steel needle (0.26 mm in diameter). The frequency of stimulation was matched as closely as possible across subjects. For manual acupuncture, the needle was rotated manually clockwise and counterclockwise at a rate of about 180 times per minute (3 cycles per second, 3 Hz). An electroacupuncture instrument (ZYZ-20GZ1, Institute of Acupuncture and Moxibustion, China Academy of Traditional Chinese Medicine, Beijing) was used to administer electroacupuncture with continuous rectangular wave form (pulse width, 30 ms) at a frequency of 3 Hz.

For each subject, before scanning started, the needle was inserted perpendicularly to the skin surface to a depth of about 1.0 cm. A superficial electrode (a transcutaneous nerve stimulation [TENS] pad, 2 cm in diameter) was applied on the palm surface opposite to the needle tip when electroacupuncture was applied. To avoid pain during acupuncture, the needle was adjusted and electrical current intensity for each subject tested before scanning and then recorded for use during scanning. To match typical clinical administration paradigms, the intensity for manual acupuncture was chosen to elicit a moderate degree of the unique acupuncture sensation called *de qi*. The intensity for electroacupuncture was also set to cause a moderate *de qi* sensation, which was generally accompanied by mild muscle movement in the index finger. Despite our efforts to match stimulation intensity, the sensations re-

ported by subjects were different for the two modalities. No quantitative measures were used to compare the two acupuncture modalities because of the inherent difficulties in exactly matching stimulation.

A block design was adopted for each functional run. We adopted a 5-minute scan time for each functional run. This started with 1 minute of rest, followed by 1 minute of acupuncture stimulation, then 1 minute of rest, followed by 1 minute of acupuncture stimulation, then 1 minute of rest again. The acupuncture stimulation was either manual or electroacupuncture during any functional run. The interval between two functional runs was approximately 3 minutes for the same acupuncture modality and at least 5 minutes between different acupuncture modalities. Acupuncture was performed by the same acupuncturist on all subjects. After scanning was completed, subjects were questioned as to the sensation that they experienced when acupuncture stimuli were applied during each run.

Apparatus and scanning procedures

fMRI scanning was conducted on a 1.5 T General Electric (GE Medical Systems, Milwaukee, WI) Signa scanner at PLA General Hospital (Beijing) using a three-axis local gradient coil with an insertable transmit-receive radiofrequency coil optimized for whole-brain echo-planar imaging (EPI). Functional imaging used a gradient-echo EPI sequence with the following parameters: 40-ms echo time, 4-second repetition time, 24-cm field of view, 64×64 pixel matrix, and 3.75×3.75 mm in plane and 7 mm through plane. Thirteen (13) contiguous axial slice locations were imaged encompassing the whole brain down to the level of the pons. Seventy-five (75) sequential images were collected at each of the slice locations. High-resolution, T1-weighted anatomic reference images were obtained as a set of 60 contiguous sagittal slices using a three-dimensional fast-spoiled gradient-echo sequence (FSPGR, GE Medical Systems, Milwaukee, WI).

For each scan, the room lights were dimmed and the subjects instructed to close their eyes. Padding was placed behind the subject's neck

and around the head as needed to relax the cervical spine and to pack the space between the head and the inner surface of the coil. Each 75-image EPI series began with two baseline images (8 seconds) to allow the MRI signal to reach equilibrium, followed by 73 images on which analysis was performed.

Data analysis

All data processing was conducted with the software package AFNI version 2.31b (Cox, 1996). Motion correction was first applied to the functional data. One subject whose fMRI time series had perceptible, residual head movements based on cinematic viewing was excluded from further analysis. Then, the two runs for each modality of acupuncture were concatenated to produce a single long functional run. Next, for each concatenated functional run (one for manual acupuncture and one for electroacupuncture) of each subject, the time points during acupuncture manipulations ($n = 60$) were compared, on a voxel-by-voxel basis, against all other time points ($n = 86$). This procedure generated statistical parametric maps (SPMs) of t deviates reflecting differences between acupuncture manipulation and baseline at each voxel location for each subject.

To perform the group analysis, individual anatomic (SPGR) scans and SPMs were then transformed into the standard stereotaxic space of Talairach and Tournoux (1988). Another subject was excluded from analysis because anatomic data were not available. To compensate for normal variation in anatomy across subjects, functional images were blurred using a 5-mm root mean square Gaussian filter to compensate for intersubject variability in anatomic and functional anatomy. A t test was then applied to the group detect the effects of manual acupuncture and electroacupuncture versus baseline on a voxel-by-voxel basis as described above for the individual fMRI data. A t test was also applied to detect voxel by voxel difference between manual and electroacupuncture. In the group average data, a t value of {3.15} ($p < 0.014$) was selected as the cutoff for statistical significance. Only clusters that consisted of more than five continuous

voxels were counted as activation. In the individual data, a p value of <0.01 was selected as the cutoff for statistical significance. Only clusters that consisted of more than three continuous voxels were counted as activation.

One individual three-dimensional SPGR data was chosen as a "standard brain" for anatomic reference. Anatomic labels for activated areas were derived by interactive three-dimensional inspection of stereotaxically registered functional and anatomical data using MCW-AFNI software and by reference to the atlas of Talairach and Tournoux (1988). Activation areas were given anatomic labels only when the borders of the area followed borders of a gyral or sulcal structure in the Talairach and Tournoux atlas and the label was supported by three-dimensional inspection of the individual Talairach anatomic data.

RESULTS

Subjective effects

Subjects were questioned as to the type and intensity of *de qi* sensation they experienced during the acupuncture scans. *De qi* is a unique sensation of soreness, numbness, tingling, fullness, heaviness, and dull ache that develops at the site of acupuncture and may spread some distance from the acupoint during needle manipulation (Stux and Pomeranz, 1997). Because all subjects had experienced acupuncture before and had some knowledge of acupuncture, it was easy for them to describe the sensations when acupuncture stimuli were applied. During manual acupuncture, all nine subjects whose fMRI data were used for analysis developed the *de qi* sensation around the acupoint during needle manipulation, and two subjects experienced *de qi* sensation spreading to the middle of the forearm arm. The sensation was mainly soreness and distension, three subjects experienced slight pain during manipulation accompanying *de qi* acupuncture sensation. During electroacupuncture, all nine subjects reported experiencing a tingling and numbness spreading to index fingers or palms, one subject experienced a tingling spreading to middle of forearm, and two subjects experienced slight

pain during stimulation accompanying the *de qi* sensation.

fMRI results

Figure 1A shows the summary statistical map from the group average data during electroacupuncture at several axial levels overlaid on the corresponding gray scale anatomic image. Electroacupuncture elicited fMRI signal increases in the contralateral precentral gyrus (M1 region that represents the hand), but not in the corresponding primary somatosensory cortex (SI) region. In addition, activation was found on secondary somatosensory cortex (SII) in the area of the central/parietal operculum. Ipsilateral activation was found in the putamen/insula. The only cluster that showed a signal decrease during electroacupuncture was the right precuneus. Table 1 provides further details of these significant signal changes.

Unlike electroacupuncture, manual acupuncture induced no fMRI signal increase in group average data but only signal decreases (Fig. 1B). These regions of fMRI signal decrease included superior temporal gyrus and putamen/insula contralateral to the site of acupuncture; posterior cingulate, superior temporal gyrus and lentiform/insula ipsilateral to the site of acupuncture. Additional details are presented in Table 2.

Direct comparison between the two acupuncture modalities indicated that electroacupuncture resulted in a statistically greater fMRI signal increase than manual acupuncture in precentral gyrus (Talairach coordinates were as follows [right to left (mm), anterior to posterior (mm), inferior to superior (mm)]) [35.5, 12.3, 60.6], postcentral gyrus [52.7, 15.9, 13.8], and insular cortex [36.3, 11.3, 18.6] on right side and superior frontal gyrus [-11.8, -9.1, 53.5] on the left side.

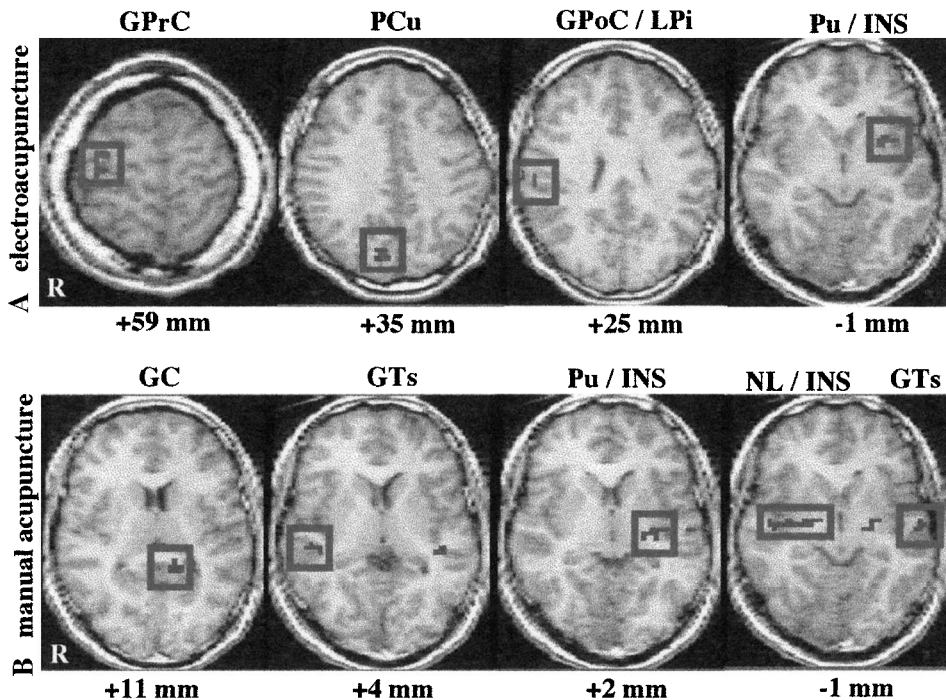


FIG. 1. Functional magnetic resonance imaging (fMRI) signal changes during electroacupuncture stimulation and signal decreases during manual acupuncture manipulation: T statistical maps of signal increases in right precentral gyrus (GPrC), right postcentral/inferior parietal lobule (GpoC/LPi), left putamen/insula (Pu/INS) and signal decrease in right precuneus (PCu) (figure 1A) induced by electroacupuncture; and signal decreases in left posterior cingulate (GC), right superior temporal gyrus (GTs), left putamen/insula (Pu/INS), left superior temporal gyrus and right lentiform/insula (NL/INS) (figure 1B) induced by manual acupuncture. $p < 0.014$ was selected as the cutoff for statistical significance. R at the left corner of the figure indicates right hemisphere of the brain. Talairach z coordinates for slices are indicated below each figure.

TABLE 1. fMRI SIGNAL CHANGES ASSOCIATED WITH ELECTROACUPUNCTURE STIMULATION IN GROUP AVERAGE DATA

Anatomy	Direction of fMRI signal change	Side	Brodmann area	Volume mm ³	Talairach Coordinates			Proportion of subjects
					RL	AP	IS	
Precentral gyrus	↑	R	4	270	32.9	15.3	59.2	9/9
Postcentral gyrus/inferior	↑	R	3/2/40	135	58	23.2	27.5	7/9
Parietal lobule								
Putamen/insula	↑	L		243	-30.4	-7.5	-0.5	6/9
Precuneus	↓	R	7	378	5.9	73.8	35.1	5/9

fMRI, functional magnetic resonance imaging; RL, right to left; AP, anterior to posterior; IS, inferior to superior.

The individual analysis of somatosensory cortex indicated that seven of nine subjects showed signal increases in SII contralateral to the site of acupuncture administration during electroacupuncture. Only three of nine subjects showed signal increases in contralateral SII during manual acupuncture. Images from a representative subject are shown in Figure 2. Figure 2A shows *t* test statistical map overlaid on the gray scale high-resolution scan at the level of the secondary somatosensory cortex and the time course of one representative voxel in this activated cluster elicited by electroacupuncture. Figure 2B shows the same brain slice with the statistical map and the time course of one representative voxel in this activated cluster elicited by manual acupuncture.

Both modalities of acupuncture were delivered in exactly the same temporal sequence to the left hand of all subjects, yet electroacupuncture induced more consistent and greater magnitude of fMRI signal increases in SII than manual acupuncture.

DISCUSSION

In this study, we used fMRI to investigate the brain regions involved in electroacupuncture

and manual acupuncture applied to LI4 acupoint of the left hand. Results showed that electroacupuncture mainly produced fMRI signal increases, while manual needle manipulation produced prominent decreases of fMRI signals. When electroacupuncture was administered, the index finger often moved and a tingling sensation commonly spread to the index finger or the palm. This may explain the electroacupuncture-induced signal increases in the hand region of precentral gyrus in every subject.

Of nine subjects whose fMRI data were used for analysis, four subjects received electroacupuncture first and five subjects received manual acupuncture first. There was no obvious condition order effect.

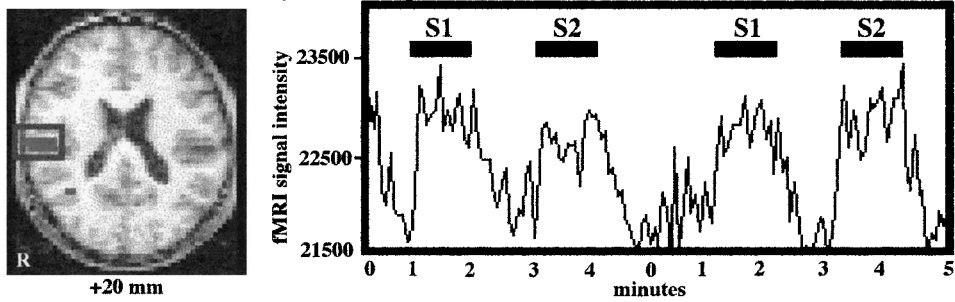
This study provides information that can be used to formulate specific testable hypotheses regarding the mechanism of clinical acupuncture efficacy. For instance, in both modalities, fMRI signal changes were detected within insula. It is well known from many published reports that insula is consistently activated during the administration of pain (Peyron et al., 2000). We noted no correlation between this insular activation & subjective reports of slight pain accompanying the *deqi* sensation. Another region that is activated by both acupuncture modalities is the putamen. The putamen is known to be cru-

TABLE 2. fMRI SIGNAL CHANGES ASSOCIATED WITH MANUAL ACUPUNCTURE MANIPULATION IN GROUP AVERAGE DATA

Anatomic localization	Direction of fMRI signal change	Side	Brodmann area	Volume mm ³	Talairach Coordinates			Proportion of subjects
					RL	AP	IS	
Posterior cingulate	↓	L	30	243	-15.4	38.6	11.5	5/9
Superior temporal gyrus	↓	L	22	189	-54.9	11.9	0.3	5/9
Superior temporal gyrus	↓	R	22	162	47.1	25.7	5.5	4/9
Putamen/insula	↓	L		486	-29.7	15.9	2.5	6/9
Lentiform/insula	↓	R		675	33.4	9.5	-0.5	5/9

fMRI, functional magnetic resonance imaging; RL, right to left; AP, anterior to posterior; IS, inferior to superior.

A. SII activation induced by electroacupuncture



B. SII activation induced by manual acupuncture

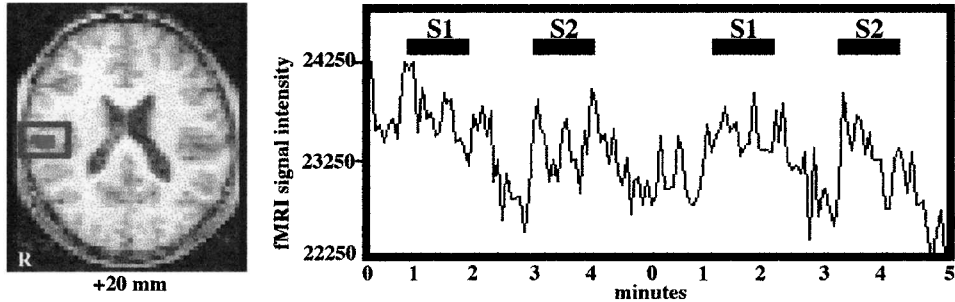


FIG. 2. Signal increases in SII in one representative subject: electroacupuncture (2A) and manual acupuncture (2B) stimulation was applied to left LI4 point; the signal increases occurred in contralateral right SII. Note that SII signal increases occurred in this subject during both treatments but only the group average data of electroacupuncture showed activation in this region. The time course of functional magnetic resonance imaging (fMRI) signal intensity change correlated with the experimental paradigm (two concatenated functional runs), S1 and S2 indicate the two acupuncture needle stimulation epochs during each functional run. $p < 6.5e-5$ was selected as the cutoff for statistical significance. R at the left corner of the figure indicates right hemisphere of the brain. Talairach z coordinates for slices are indicated below each figure.

cial to motor activity. This may help to explain the efficacy of acupuncture treatment to help temporarily reduce symptom severity in movement disorders such as Parkinson's disease (Manyam and Sanchez-Ramos, 1999).

Previous fMRI studies report that *de qi* caused by manual acupuncture needle manipulation is associated with more widespread signal decreases than reported here (Hui et al., 2000; Wu et al., 1999). This may result from two factors. The first is a technical limitation. We scanned the whole brain with 7-mm thick slices, which may result in the inability to detect significant signal decrease in small brain structures. Another factor is that all our subjects were familiar with acupuncture, which may diminish the emotional arousing aspects of acupuncture stimulation (e.g., anxiousness, curiosity, and even fear). This might produce fewer changes in fMRI signal changes in the limbic system, particularly the amygdala, structures that are critical to the expression of these emotions (Adolphs, 2001).

Unlike manual acupuncture, electroacupuncture mainly induced signal increases. There were no significant signal decreases in deep structures even at lower threshold ($p < 0.05$). One explanation is that different *de qi* sensations, and correspondingly different sensory nerve fibers, are activated by the two acupuncture modalities. Manual acupuncture mainly induced soreness, fullness, and distention, while electroacupuncture mainly produced tingling and numbness. Wang et al. (1985) used action potential recordings to categorize the nerve fibers involved in different *de qi* sensation, the results showed that numbness was conveyed mainly by $A\beta/\gamma$ fibers, distension and heaviness by $A\sigma$ fiber, and soreness by C fibers (Wang et al., 1985). It is known that $A\beta$ fibers mainly terminate in lamina III to VI of the dorsal horn, while $A\sigma$ fibers terminate on large cells in lamina I/II and C fibers mainly make synaptic contact with substantia gelatinosa cells in lamina II (Hendry et al., 1999). Thus, different acupuncture modalities may

trigger different brain networks based on the types of afferent input. This suggests that for further studies, *de qi* may be too general a term to classify the many sensations induced by acupuncture.

Although our experiment indicates that electroacupuncture induced more fMRI signal increases than manual acupuncture, and manual acupuncture induced more signal decreases, we cannot conclude that electroacupuncture is more "powerful" than manual acupuncture. Nor can we conclude that electroacupuncture mainly has an excitatory effect on the brain and manual acupuncture mainly has an inhibitory effect, because the coupling between fMRI bold signal changes and neural activity is still an area of active investigation. Further experiments to investigate these results are clearly desired, beginning with efforts to link clinically relevant effects of acupuncture with these fMRI findings and extension of the findings to clinical populations.

CONCLUSION

Using fMRI, we found that manual stimulation of an acupuncture needle placed in left LI4 mainly produced fMRI signal decreases, while electroacupuncture stimulation of the same needle in the exact same location mainly produced fMRI signal increases in the same subjects during the same scanning session. These results indicate that fMRI detects different patterns of brain activity during the two acupuncture modalities. It suggests that different brain mechanisms may be recruited during manual and electroacupuncture stimulation. Additional experiments are required to determine the common neural changes by which different acupuncture modalities regulate multiple physiological systems and achieve diverse therapeutic effects such as acupuncture analgesia and treatment of movement disorders. Further experiments using these noninvasive brain imaging methods to investigate the correlation between brain activity patterns and acupoint stimulation variables such as stimulation methods and intensities (corresponding with different *de qi* sensation and different nerve fibers activated) will provide additional clues as to the neural mechanism of acupuncture.

It is hoped that this will then lead to the improvements in acupuncture clinical efficacy.

ACKNOWLEDGMENTS

The authors thank Ken Kwong and Pheobe Chen in the Nuclear Magnetic Resonance center of Massachusetts General Hospital (MGH-NMR center) for their help with fMRI data analysis, and Iris Chen for her valuable comments on the manuscript.

REFERENCES

- Adolphs R. The neurobiology of social cognition. *Curr Opin Neurobiol* 2001;11:231-239.
- Bucinskaite V, Lundeberg T, Stenfors C, Ekblom A, Dahlin L, Theodorsson E. Effects of electro-acupuncture and physical exercise on regional concentrations of neuropeptides in rat brain. *Brain Res* 1994;666:128-132.
- Cho ZH, Chung SC, Jones JP, Park JB, Park HJ, Lee HJ, Wong EK, Min BI. New findings of the correlation between acupoints and corresponding brain cortices using functional MRI. *Proc Natl Acad Sci USA* 1998;95:2670-2673.
- Cox RW. AFNI: Software for analysis and visualization of functional magnetic resonance neuroimages. *Comp Biomed Res* 1996;29:162-173.
- Dawidson I, Blom M, Lundeberg T, Angmar-Mansson B. The influence of acupuncture on salivary flow rates in healthy subjects. *Oral Rehabil* 1997;24:204-208.
- Diehl DL, Kaplan G, Coulter I, Glik D, Hurwitz EL. Use of acupuncture by American physicians. *J Altern Complement Med* 1997;3:119-126.
- Eisenberg DM, Davis RB, Ettner SL, Appel S, Wilkey S, Van Rompay M, Kessler RC. Trends in alternative medicine use in the United States. *JAMA* 1998;280:1569-1575.
- Eisenberg DM, Kessler RC, Foster C, Norlock FE, Calkins DR, Delbanco TL. Unconventional medicine in the United States. Prevalence, costs, and patterns of use. *N Engl J Med* 1993;328:246-252.
- Hendry SHC, Hsiao SS, Bushnell MC. Somatic sensation. In: Zigmond MJ, Bloom FE, Landis SC, Roberts JL, Squire LR, eds. *Fundamental Neuroscience*. San Diego: Academic Press, 1999:761-789.
- Hui KK, Liu J, Makris N, Gollub RL, Chen AJ, Moore CI, Kennedy DN, Rosen BR, Kwong K. Acupuncture modulates the limbic system and subcortical gray structures of the human brain: Evidence from fMRI studies in normal subjects. *Hum Brain Mapp* 2000;9:13-25.
- Manyam BV, Sanchez-Ramos JR. Traditional and complementary therapies in Parkinson's disease. *Adv Neurol* 1999;80:565-574.
- NIH Consensus Development Panel on Acupuncture. Acupuncture. *JAMA* 1998;280:1518-1524.

- Peyron R, Laurent B, Garcia-Larrea L. Functional imaging of brain responses to pain. A review and meta-analysis. *Neurophysiol Clin* 2000;30:263–288.
- Saletu B, Saletu M, Brown M, Stern J, Sletten I, Ulett G. Hypno-analgesia and acupuncture analgesia: A neurophysiological reality? *Neuropsychobiology* 1975;1: 218–242.
- Stux G, Pomeranz B. *Basics of Acupuncture*. Berlin: Springer-Verlag, 1997:204.
- Talairach J, Tourneaux P. *Co-Planar Stereotaxic Atlas of the Human Brain*. New York: Thieme Medical, 1988.
- Wang K, Yao S, Xian Y, Hou Z. A study on the receptive field of acupoints and the relationship between characteristics of needling sensation and groups of afferent fibres. *Scientia Sinica (B)* 1985;28:963–971.
- Wu, MT, Hsieh JC, Xiong J, Yang CF, Pan HB, Chen YC, Tsai G, Rosen BR, Kwong KK. Central nervous pathway for acupuncture stimulation: localization of processing with functional MR imaging of the brain—Preliminary experience. *Radiology* 1999;212:133–141.

Address reprint requests to:

Jian Kong, M.S., Lic.Ac.

Massachusetts General Hospital East

149 13th Street, Room 9109

Charlestown, MA 02129

E-mail: kongj@nmr.mgh.harvard.edu